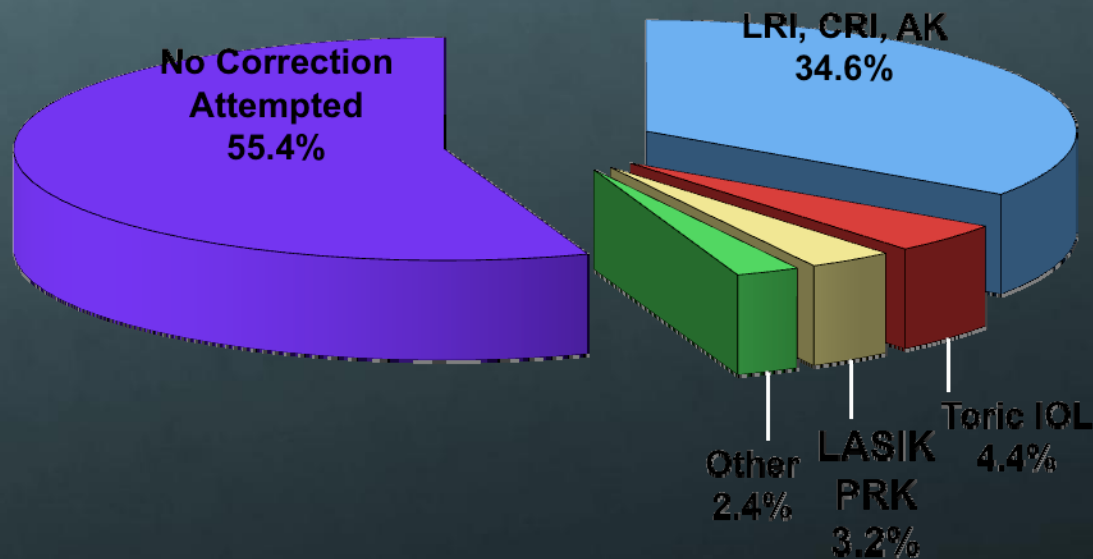






Astigmatism Correction

30% of patients have 1.0D or more of pre-existing astigmatism



Refractive Management: Intraoperative Solutions

-  Calculating Astigmatism
-  On-Axis Incisions
-  Limbal Relaxing Incisions (LRI's)
-  Toric IOLs

Intraoperative Solutions: Calculating Astigmatism

- 🌐 Astigmatism treatment is based on
 - 🌐 Preoperative corneal astigmatism, and
 - 🌐 Surgically induced astigmatism
- 🌐 Need to know how much astigmatism your cataract incision induces



Intraoperative Solutions: LRI's Made Simple

- 🌐 **< 0.75 D Cyl: Intraoperative LRI or perform an On-Axis incision**
 - 🌐 If the astigmatism axis is within 15 degrees of the incision then move your incision to the axis
 - 🌐 If the astigmatism axis is outside of 15 degrees from the incision site, place your incisions where comfortable and perform LRI
- 🌐 **0.75-1.5D Cyl: Perform intraoperative LRI**
- 🌐 **> 1.5D Cyl: Intraoperative LRI to debulk astigmatism + Post-op LASIK or PRK**

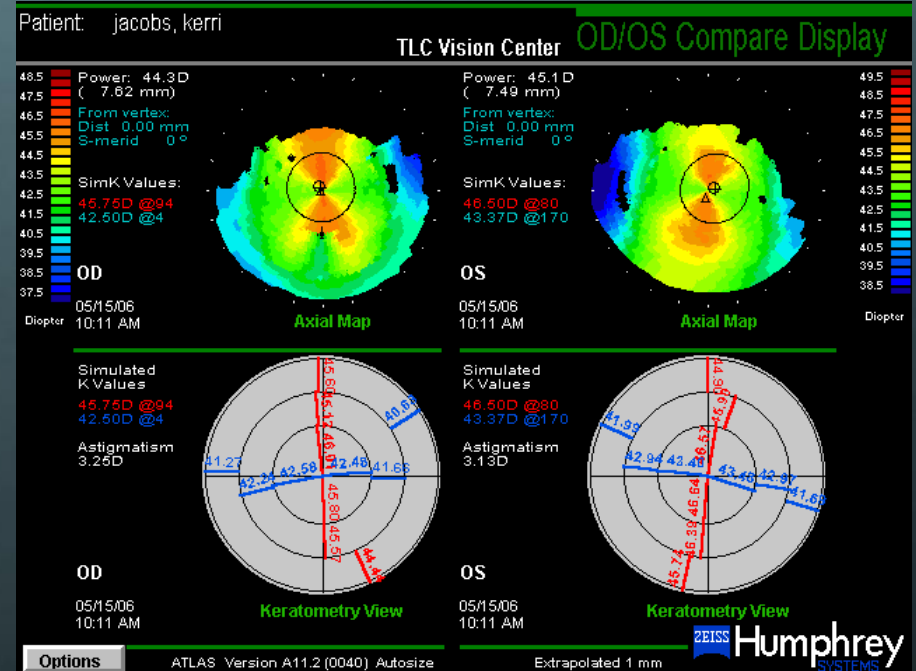
Pseudophakic Refractive Management

Intraoperative Solutions: Overcoming LRI Challenges

Understanding topography

Must become adept at reading topo maps to determine where to place the incisions

Planning requires a little extra attention





Intraoperative Solutions: Overcoming LRI Challenges

- Placement of incisions
 - Must maintain correct orientation during surgery.
 - Mark 90 degree axis while sitting up to avoid cyclotorsion
 - Many template instruments available



Dell Astigmatism Marker
Rhein Medical



Intraoperative Solutions: Overcoming LRI Challenges

- 🌐 Making the incisions
 - 🌐 Diamond knife required
 - 🌐 Choose a knife w/pre-set depth of 500-600 μ m
 - 🌐 Eliminates need for pachymetry or knife calibration
 - 🌐 Well within skill set of any cataract surgeon



Intraoperative Solutions: Getting Started with LRI's

Step 1: Start in OR with a peribulbar block

Step 2: Pre-set 0.6 mm depth diamond blade

Step 3: Limbal relaxing incision $\frac{1}{2}$ mm in from limbus.

Step 4: Fixate globe with .12 forceps 180 degrees away from incision, or use a fixation ring with opening at axis to be treated.



Intraoperative Solutions: Getting Started with LRI's

Step 5: Use upside down topography and center incisions on steep axis (+cylinder).

Step 6: Set diamond knife perpendicular in cornea, hold like a dart, allow blade to seat fully then pull slowly towards surgeon.







Knowledge Review



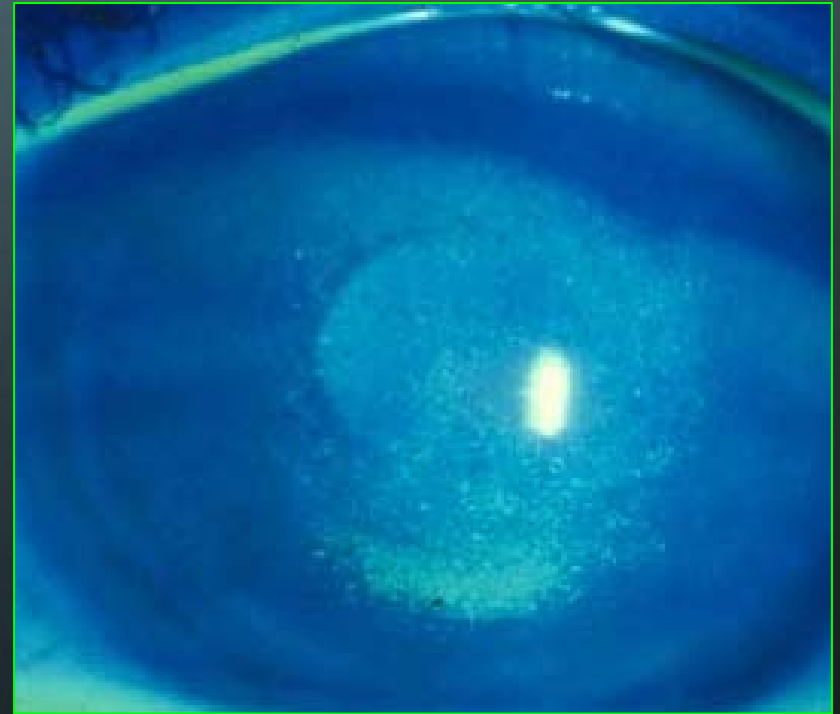
- 🌐 Do you currently correct astigmatism intraoperatively?
- 🌐 Do you currently perform on-axis incisions?
- 🌐 What percentage of your patients do you perform LRI's to manage astigmatism intraoperatively?

Postoperative Solutions:

-  **C**ornea and ocular surface disease
-  **C**ylinder and residual refractive error
-  **C**apsular opacities
-  **C**ME

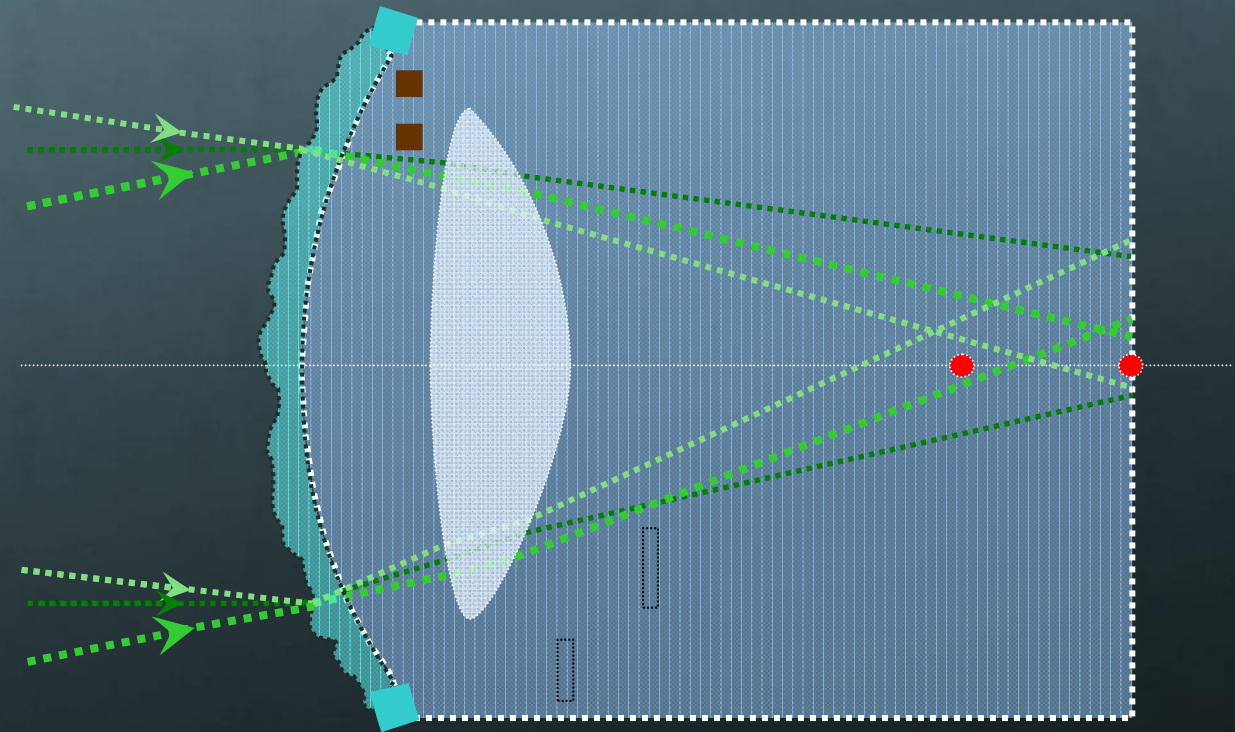
Premium Surgical Environment: The Ocular Surface

- 🌐 The tear film is the most important refracting surface of the eye
- 🌐 Lubricants Important
- 🌐 Cyclosporine helpful



Premium Surgical Environment: The Ocular Surface

- 🌐 Ocular surface disruption induces distortion can be magnified by a presbyopia-correcting IOL



YAG Capsulotomy

- 🌐 Decreased reading vision is often earliest sign of capsular thickening.
- 🌐 Usually YAG after 3 months but may consider earlier depending on patient symptoms.
- 🌐 Stay within optic.

Technique & Technologies: Pharmaceuticals

- 🌐 Topical NSAIDs have been shown to optimize surgical outcomes following cataract surgery*
- 🌐 Less CME
- 🌐 Less pain and inflammation
- 🌐 Shorter surgical times
- 🌐 Better quality of vision with multifocal IOLs



Knowledge Review



- 🌐 What tips can you share for prevent CME?
- 🌐 How do you currently manage dry eye in PCIOL patients?

Postoperative Solutions: Residual/Induced Cylinder

LRI vs Excimer Laser Enhancement

 < 1D Cylinder: Additional LRI or LVC





 > 1D Cylinder: LVC

Postoperative Solutions: Residual/Induced Cylinder

- 🌐 **Axis of astigmatism has moved to opposite axis:**
 - 🌐 **Do not perform a touch-up LRI**
 - 🌐 **Suture the wound if significant overcorrection**
 - 🌐 **Wait 3 months to remove sutures and then Laser Vision Correction**
 - 🌐 **In small overcorrections consider PRK**

Postoperative Solutions: Residual Spherical Error

Without astigmatism:

-  Laser vision correction – *Preferred*
-  *Make sure that lens is still accommodating without vault*
-  IOL Exchange
-  Piggyback IOL- *Do not use Minus lenses in the sulcus*

With astigmatism:

-  Laser vision correction

Postoperative Solutions: Laser Vision Correction


 Do you need to learn LASIK?

 **NO!**





 Start with PRK

 Less stressful

 Excellent, repeatable results

 Older patients often have less adherent epithelium and will do well with PRK

Postoperative Solutions: Overcoming LVC Challenges

-  Optimize ocular surface preop
-  Perform custom correction if possible
-  Perform surface ablation if dry eye is a concern
-  Determine fee structure in advance

Refractive Management: Summary

- 🌐 5 steps to start down the path of astigmatism correction:
 - 🌐 Maximize health of ocular surface
 - 🌐 Start performing/increase comfort w/topography
 - 🌐 Begin with on-axis incisions for minor reductions in astigmatism
 - 🌐 Learn to perform LRIs
 - 🌐 Perform or outsource LVC enhancements